

# Use Of Silicone Products in Treating Peristomal Skin Breakdown

Authors: Michelle Rice, RN, BSN, CWOCN • Jane Fellows, RN, BSN, CWOCN • Jan Johnson, RN, ANP, CWOCN, FNP • Julia Q. Walker, RN, FNP, CWOCN Duke University Hospital System



## CASE STUDY ONE

Ms. B, a 76 year-old female, presented on 09/21/04 with a two year history of peristomal pyoderma gangrenosum. History included a vesico-vaginal fistula repair with a urostomy in 2000. She performed daily pouch changes with pain 04/10. Previous treatments included topical steroids, cyclosporin and antifungals.

### TREATMENT PLAN

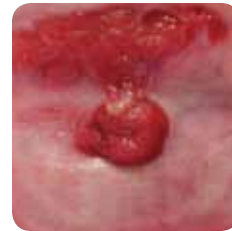To simplify Ms. B's pouching procedure and to decrease the pain, pimecrolimus cream was applied to the peristomal ulcer and covered with a soft silicone foam dressing. A convex urostomy pouch was applied; her pouch wear time eventually increased to 7-8 days. She remains on cyclosporin 100mg daily. Her pain is consistently 0/10.

### PATIENT EDUCATION

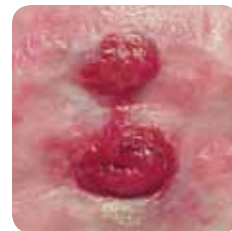The patient was instructed in the new pouching protocol, including use of topical therapy, local wound care and pouching. She was also instructed to obtain monthly lab work.

### SUMMARY

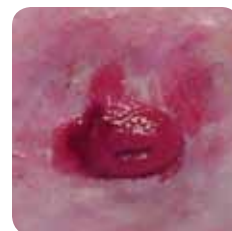Using the soft silicone foam dressing provided pain relief, drainage management, extended pouch wear time and a cost-effective treatment. Ms. B is thrilled, confident, and secure with her new pouching procedure.



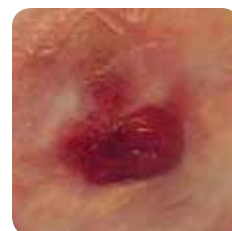
09/21/04



12/07/04



12/07/04



02/15/05

## CASE STUDY TWO

Mrs. S, a 57 year-old female with Crohn's disease, presented with peristomal pyoderma gangrenosum. History of multiple eruptions since March 2003. Treatments have included peristomal steroid injections, systemic corticosteroids and topical steroids with hydrocolloid cover dressings. She had less than one day wear time and was experiencing significant pain (8/10) with pouch changes.

### TREATMENT PLAN

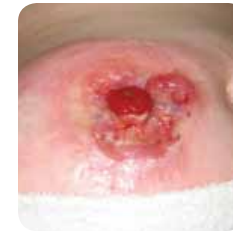Tacrolimus with orabase and benzocaine covered with a hydrocolloid was initiated and resulted in a decrease in pain (2/10) with pouch changes, but no increase in wear time. A soft silicone foam was initiated over the topical preparation along with a 2-piece light convex pouching system. This resulted in an immediate increase in wear time to 3 days and a reduction in pain (0/10) with a pouch change.

### PATIENT EDUCATION

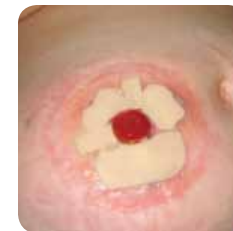Mrs. S. was instructed to continue with the tacrolimus/orabase mixture, the use of a soft silicone foam dressing and the new pouching system.

### SUMMARY

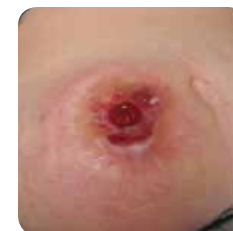Use of a soft silicone foam dressing managed the wound drainage, decreased the pain during pouch changes and increased wear time to 3-4 days.



01/03/05



01/12/05



02/01/05

## CASE STUDY THREE

Baby boy H, a 14 month-old infant, presented on 02/16/05 with significant friable and painful peristomal skin breakdown due to leakage and frequent pouch changes. The patient has extensive post-operative scarring, which has created a very irregular pouching surface. The patient was born prematurely with NEC necessitating removal of much of his colon and small intestine.

### TREATMENT PLAN

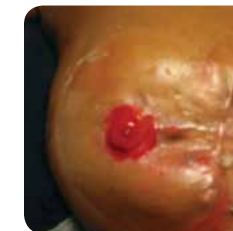To decrease the pain associated with the frequent pouch changes, the ostomy team elected to initiate the use of a soft silicone foam dressing. The dressing was placed around the stoma to cover the area of breakdown. The pouching system was then placed over the soft silicone foam. Though the peristomal skin breakdown continued to be a challenge, the baby did not experience pain as evidenced by his lack of crying.

### PATIENT EDUCATION

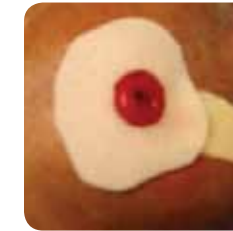
Step-by-step visual and written instructions were posted in patient's room to assist nursing staff and improve consistency of care.

### SUMMARY

The use of the soft silicone foam dressing was instrumental in decreasing pain during pouch changes and resulted in an improvement in patient quality of care.



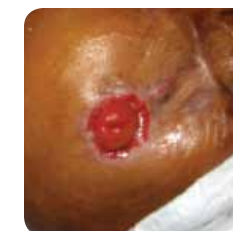02/16/05



02/16/05



02/16/05



02/18/05

## CASE STUDY FOUR

Mr. T, a 75 year-old male, presented on 4/19/05 with complaints of peristomal ulcerations and moderate pain for five months. The patient had frequent pouch leakage and was only able to maintain a wear time of 2 days. Current Diagnosis: peristomal pyoderma gangrenosum.

### TREATMENT PLAN

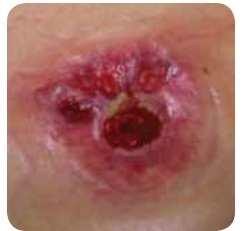To decrease the pain associated with pouch changes and to heal the ulcerations, a mixture of tacrolimus and orabase with benzocaine was applied to the wound site and covered with a soft silicone foam dressing. A soft, convex, one-piece pouching system with a belt was applied.

### PATIENT EDUCATION

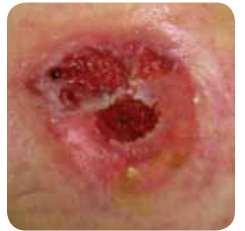The patient and spouse were instructed on the new pouching system, use of topical ointment and application of the silicone foam dressing.

### SUMMARY

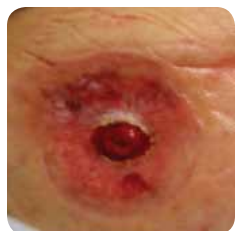Use of the soft silicone foam dressing used with the topical ointment has decreased the pain during pouch changes and demonstrated a significant improvement in wound healing.



04/19/05



04/26/05



05/10/05

**PRODUCT NOTATION** Mepilex® Lite Mölnlycke Health Care US, LLC, Norcross, GA 30092

**FINANCIAL ASSISTANCE/DISCLOSURE** Mölnlycke Health Care US, LLC. provided assistance with poster design.

The Mölnlycke Health Care, Mepilex names and respective logos are registered trademarks of Mölnlycke Health Care AB. Distributed by Mölnlycke Health Care US, LLC, Norcross, Georgia 30092.





## Use Of Silicone Products in Treating Peristomal Skin Breakdown

### Authors:

Michelle Rice, RN, BSN, CWOCN  
Jane Fellows, RN, BSN, CWOCN  
Jan Johnson, RN, ANP, CWOCN, FNP  
Julia Q. Walker, RN, FNP, CWOCN  
Duke University Hospital System

